

Safer shunt insertion during carotid endarterectomy

Michael J. Beezley, M.D., *Shawnee Mission, Kan.*

The use of shunts during carotid surgery may decrease the risk of perioperative stroke by allowing continued perfusion during the procedure. However, there are risks inherent with shunt usage that occur mainly during insertion. A brief clinical study illustrates the risk of shunt-induced emboli and a technique is described for safer shunt insertion. (*J VASC SURG* 1985; 2:607-9.)

There are numerous shunt-related causes of cerebral deficits during carotid surgery. Unless the shunt is quickly inserted, cerebral anoxia may occur. Unless the shunt is properly positioned, shunt thrombosis may result. Unless it is carefully inserted, there may be air or atheromatous emboli or disruption of and possible raising of an intimal flap. The incidence of cerebral deficits as reported by Thompson et al.,¹ Prileau et al.,² Easton and Sherman,³ and others who routinely use a shunt ranges from approximately 2% to 14%. Baker et al.⁴ stated that in their opinion the incidence of stroke resulting from shunt-induced emboli probably approaches the incidence of ischemic stroke without the shunt.

Traditionally shunts have been inserted into the internal carotid artery, back-flushed, and then inserted into the proximal common carotid artery. Several reports have been published describing this method of shunt insertion.^{1,5-8} Towne and Bernhard⁹ reported a perioperative stroke caused by atheromatous emboli actually seen passing through the shunt inserted in this manner.

The purpose of this article is twofold: to point out the potential risk of embolization with insertion of the shunt in the traditional manner and to describe a method of shunt insertion that will reduce shunt-related causes of perioperative stroke.

MATERIAL AND METHODS

To illustrate the increased risk of emboli as a result of insertion of shunts in the traditional manner, a series of 15 consecutive patients was studied pro-

spectively. After informed consent was obtained, all 15 patients underwent a unilateral carotid endarterectomy under cervical block anesthetic and none required a shunt for cerebral protection. Before endarterectomy was performed, a Javid shunt was inserted into the common carotid artery and secured. An occluding Kelley clamp was released and 10 to 15 ml of blood were flushed through the shunt into an attached macropore filter (Fig. 1). The shunt was removed and flushed with heparinized saline solution. The carotid endarterectomy was then completed uneventfully in all 15 patients without the shunt. The macropore filter was examined and any material seen was sent for pathologic evaluation. Atherosclerotic emboli passed through the shunt, which was trapped by the macropore filter, in two of the 15 patients. This small series of patients shows that atheromatous debris may be picked up and passed through the shunt after the proximal end of the shunt has been inserted.

OPERATIVE TECHNIQUE

The following is a description of the method we prefer for shunt placement to avoid this potential problem. Before the procedure begins, Kelley clamps are placed across the heparinized saline solution-filled shunt 1 inch from each end at a slight angle. After heparinization is done, occluding clamps are placed across the isolated internal, common, and external carotid arteries. When the need for a shunt has been determined, the arteriotomy is made. With the proximal Kelley clamp as a handle, the proximal end of the shunt is inserted into the common carotid artery as the initial step of shunt insertion (Fig. 2). The surgeon releases the distal Kelley clamp momentarily and allows 5 to 10 ml of blood to flush out any atheromatous debris that may have been scraped off the wall of the common carotid artery by

From the Department of Surgery, David Grant United States Air Force Medical Center, Travis AFB, Calif.
Presented at the Thirty-first Annual Symposium of the Society of Air Force Clinical Surgeons, San Antonio, Tex., May 1-5, 1983.
Reprint requests: Michael J. Beezley, M.D., 8800 W. 75th St., Suite 115, Shawnee Mission, KS 66204.

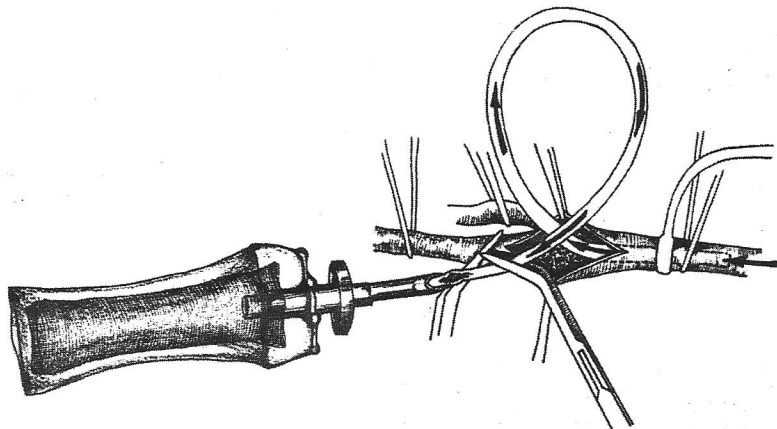


Fig. 1. To demonstrate potential occurrence of emboli, 10 to 15 ml of blood were flushed through Javid shunt into filter after its insertion into common carotid artery. (Not a routine technical step.—*Editor*)

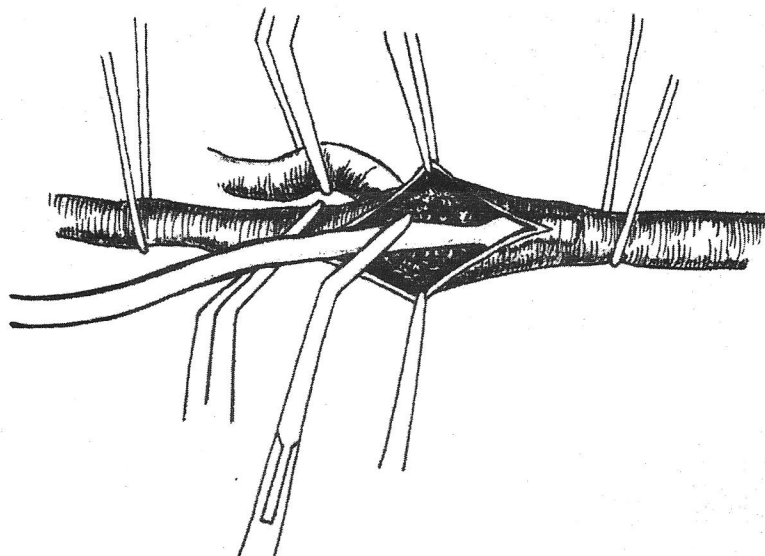


Fig. 2. Insertion of large end of shunt into common carotid artery as initial step in shunt insertion.

insertion of the proximal end of the shunt (Fig. 3). Using the Kelley clamp to partially occlude the distal end of the shunt and controlling the flow of blood through the shunt to a constant drip, the surgeon slips the distal end of the shunt into the nondiseased portion of the internal carotid artery as the assistant releases the occluding clamp to allow internal carotid back-bleeding. Using the Kelley clamp as a handle without occluding the shunt, the surgeon advances the distal end of the shunt to the desired depth and secures it, which allows forward flow.

DISCUSSION

The main difference between the traditional method of shunt insertion and the one described is the end inserted first. Several authors advocate shunt placement by insertion of the distal end first.^{1,5-8} Back-bleeding is allowed from the internal carotid artery as the proximal end is inserted into the common carotid artery. The disadvantage is that one is pushing the shunt into the common carotid artery, which usually contains a soft and thickened but smooth atheromatous intima. A potentially disastrous result

is the possibility of the intima occasionally becoming loosened and embolizing distally once forward flow is allowed. The brief study of 15 patients was not designed to determine the frequency of embolization but simply to show that macroscopic embolization of atheromatous debris through shunts does occur. Perhaps microscopic embolization occurs just as frequently. Debris scraped up in this manner and passed through the shunt may cause a cerebral deficit if forward flow is allowed with the distal end of the shunt already secured. This debris can still be picked up with the technique described but is flushed out of the shunt before its insertion into the internal carotid artery. The technique of dripping blood through the shunt with partial occlusion of the Kelley clamp while back-bleeding from the internal carotid artery during insertion makes an air embolus highly unlikely. Since the arteriotomy should be opened past any plaque into the normal internal carotid artery, there should be little risk of raising an intimal flap if the shunt is inserted carefully. Debris is much more likely to be loosened at the proximal end of the shunt in the common carotid artery.

SUMMARY

A macropore filter was used to trap potential emboli during insertion of the proximal end of the shunt during 15 carotid endarterectomies. A method of shunt insertion during carotid surgery has been described that may reduce the incidence of air or atheromatous embolization, which might otherwise occur if shunts are placed according to the traditional method.

REFERENCES

1. Thompson JE, Patman RD, Talkington CM. Carotid surgery for cerebrovascular insufficiency. *Curr Probl Surg* 1978;15.

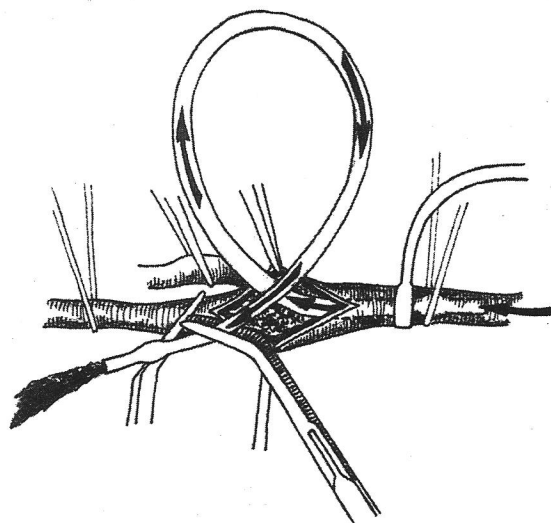


Fig. 3. Flushing of blood through shunt that discards any scraped atheromatous debris that may have been picked up during insertion of proximal end of shunt.

2. Prileau Jr WH, Aiken AF, Hairston P. Carotid endarterectomy: Neurologic complications as related to surgical techniques. *Ann Surg* 1977; 185:678-83.
3. Easton JD, Sherman DG. Stroke and mortality rate in carotid endarterectomy: 228 consecutive operations. *Stroke* 1977; 8:565-8.
4. Baker WH, Dorner DB, Barnes RW. Carotid endarterectomy: Is an indwelling shunt necessary? *Surgery* 1977; 82:321-6.
5. Wylie EJ, Stoney RJ, Ehrenfeld WK. *Manual of vascular surgery*, vol 1. New York: Springer-Verlag New York Inc, 1980.
6. Rutherford RB. *Vascular surgery*. Philadelphia: WB Saunders Co, 1977.
7. Persson AV, Griffey SP. Carotid endarterectomy. *Surg Clin North Am* 1980; 60:503-12.
8. Sohiro J. Routine use of shunt for CEA. *Am J Surg* 1981; 142:735-8.
9. Towne JB, Bernhard VM. Neurologic deficit following carotid endarterectomy. *Surg Gynecol Obstet* 1982; 154:819-52.